

ONCOLOGY

A CYTOCHEMICAL INVESTIGATION OF THE NUCLEIC ACIDS, PROTEINS AND POLYSACCHARIDES IN MALIGNANT TUMORS OF THE UTERINE CERVIX AND BREAST IN HUMANS

I. A. Shumova

From the Department of General Biology of the Leningrad Institute of Preventive Medicine

(Received October 23, 1958. Presented by Active Member AMN SSSR N. G. Khlopin)

A large number of papers has recently been published, devoted to the explanation of the role of nucleic acids in processes taking place in tumors [1, 5, 9, 10, 11, 12, 15]. It must be pointed out, however, that experimental investigations predominate among this research.

After the work of Warburg [16], great importance began to be attached to polysaccharides in the phenomena of malignant change. There have been few cytochemical investigations, however, devoted to their study [8, 13, 14].

In the present work, particular attention has been directed to the study of nucleic acids, proteins and also polysaccharides in cancer cells, and to the comparison of the patterns observed with the normal. At the same time an attempt was made to establish signs as criteria in the early diagnosis of malignant tissue.

EXPERIMENTAL METHOD

In this research we used clinical material (biopsy specimens, organs removed at operation) from patients with carcinoma of the breast and uterine cervix. As controls we used tissues from these organs taken from the cadavers of persons who had died from various causes (but not from malignant disease), or removed in the course of plastic operations.

Fragments of the organs were fixed in Carnoy's mixture, in alcohol with formalin and also in 10% neutral formalin, and embedded in paraffin wax.

Desoxyribonucleic acid (DNA) was revealed by Feulgen's stain, ribonucleic acid (RNA) by staining with methyl green and pyronin by Unna's method. In order to remove the nucleic acids, sections were treated with a 5% solution of trichloroacetic acid (90°, 15 minutes), and to dissolve the RNA we used hydrolysis in normal HCl (60°, 6 minutes).

The protein composition was determined on the basis of staining the preparations with fast green at pH = 2.2 (total protein) and pH = 8.0 (proteins of the histone type). Polysaccharides were stained by the Shabadash-Hotchkiss method. Controls were set up with ptyalin (60 minutes at 37°) and with distilled water (60 minutes at 37°).

Material was used from more than 100 patients, including 64 with carcinoma of the uterine cervix and breast. In selecting the material, attention was paid to the clinical and pathologicoanatomical data on each patient.

The material investigated included the main clinical stages of malignant disease. The microscopic picture also included the main forms of squamous-cell carcinoma of the uterine cervix (carcinoma "in situ", squamous-cell carcinoma without marked keratinization, keratinizing and undifferentiated carcinoma) and of carcinoma of the breast (adenocarcinoma, scirrhous, encephaloid and solid carcinoma).

EXPERIMENTAL RESULTS

In the normal stratified squamous epithelium of the vaginal part of the uterine cervix, DNA is mainly contained in the nuclei of the basal layer; only insignificant amounts of DNA are present in the cells of the remaining layers. The epithelium of the terminal divisions of the breast also have a comparatively low DNA content.

Weak pyroninophilia was found in the cytoplasm of the cells of the basal layer of epithelium of the vaginal part of the cervix; in the glandular epithelium of the breast this was not observed in the majority of cases; the RNA content increased the nearer the layer to the stratum corneum. It was also present in the nucleoli, in which there is normally only a small amount or none at all. These findings were in agreement with those in the literature [7].

The intensity of the staining for proteins of the histone type and its localization in normal cells corresponded to the picture observed when Feulgen's method for DNA was used.

The epithelium of the vaginal part of the uterine cervix is normally rich in polysaccharides, which, in the form of granules, fill the cytoplasm of all the cells except those of the basal layer. The cells of the terminal divisions of the breast are without polysaccharides. These are found in the form of large granules in the lumen of the alveoli. The connective tissue stroma of the uterine cervix and breast gives a strongly positive diffuse periodic acid - Schiff reaction.

Since treatment with pyralin did not lead to weakening of the intensity of staining, it may be considered that this particular polysaccharide was not glycogen, and it must therefore be regarded as a mucopolysaccharide.

Our investigations confirmed the data in the literature on the significantly greater nucleic acid content of tumors by comparison with normal tissue [2, 3, 4, 5, 11].

At the present time two types of cells are distinguished in malignant tumors. The cells of the first type (A) are situated in the growing, peripheral part of the tumor; cells of the second type (B) enter into the composition of the inner zone, in which the processes of protein synthesis and growth are very greatly reduced in intensity, and in which mitoses are absent [9].

Type A cells are characterized by a high DNA content in the nucleus and a high RNA content in the cytoplasm and nucleoli. Mitoses are common in these cells. The cytoplasm of the type B cells is poor in RNA, and their nuclei are less rich in chromatin than those of the type A cells; their nucleoli are larger, 3-4 in number, and mitoses are absent. These cells are in a transitional state, after which senescence and degradation begin [5].

Our investigations confirmed the presence of these two types of cells, but the material which we examined led to the necessity of distinguishing a third type of cells which were found in the malignant tumors of the uterine cervix and breast. These cells were characterized by a high DNA content in their nuclei, whereas the pyroninophilia of their cytoplasm was very weak, and the RNA content of their nucleoli was low or it was absent altogether (Fig. 1, a). The nuclei of these cells were often polymorphic; they gave a strong Feulgen reaction and stained intensively with fast green for proteins of the histone type. Mitoses were found among them.

Cells of this type were predominant in such forms of cancer as carcinoma "in situ", which is a malignant process of the epithelium of the uterine cervix that has not yet penetrated into neighboring tissues.

The majority of workers regard it as the initial stage of carcinoma [6]. These cells were also observed at the periphery of the alveoli of the carcinoma.

According to our observations, cells of this type were characteristic of early stages of development of carcinoma, and we therefore referred to them as type A₁.

Analysis of the different forms of carcinoma of the uterine cervix and breast was made in respect to the three types of cell (A₁, A and B) which have been enumerated. A definite trend was established in the

quantitative proportions of these cell types in the various forms of carcinoma of both the cervix and breast.

In carcinoma "in situ" of the uterine cervix, for example, cells of types A_1 and A predominated, especially the first. In squamous-cell carcinoma, cells of types A_1 and A again predominated, but the second of these was more common. Alongside these, type B cells were also present. In the undifferentiated carcinoma, cells of types A and B were most common and there were few type A_1 cells (Fig. 1,b).

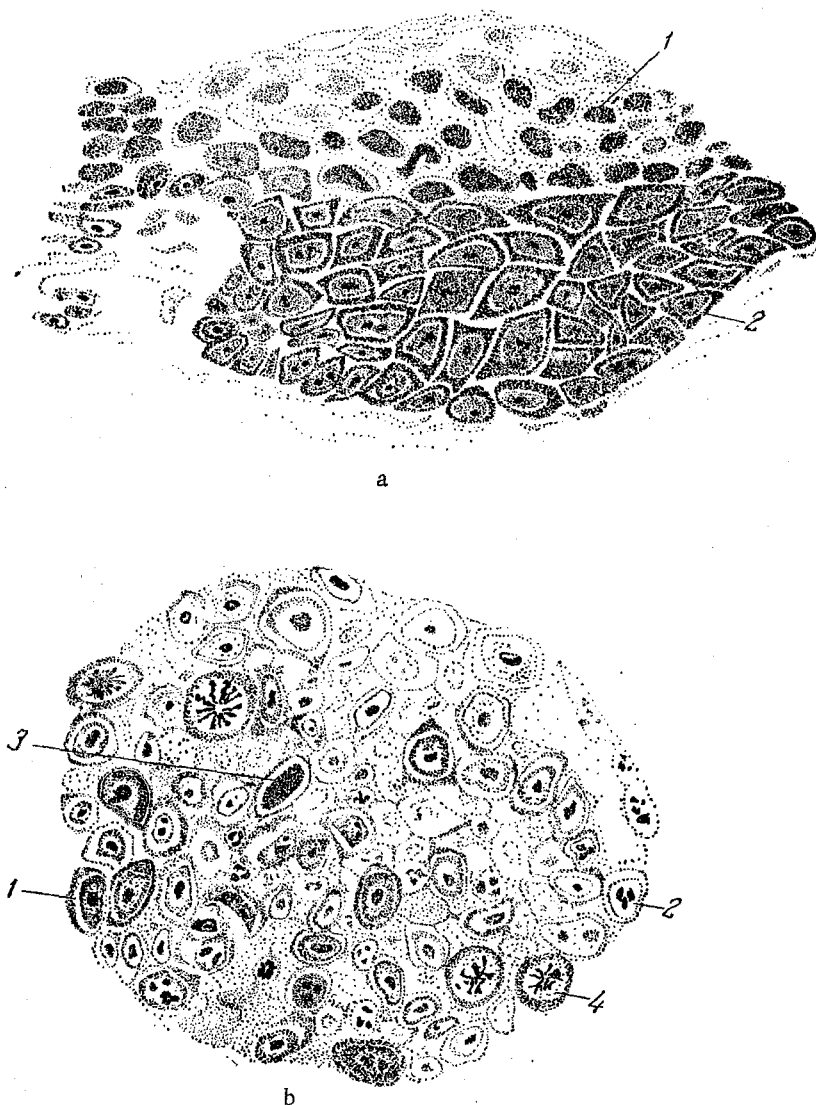


Fig. 1. a) Carcinoma "in situ" of the uterine cervix. Atypical stratified epithelium is infiltrating the submucosal tissue along the course of the glands: type A_1 cells — the cell nuclei are rich in DNA, pyroninophilia of the cytoplasm and nucleolus is feebly shown or absent (1); type A cells — the cell nuclei contain DNA, the cytoplasm is rich in RNA, nucleoli are seen (2). Fixing agent — Carnoy's fluid. Stained by Unna's method; b) undifferentiated carcinoma of the uterine cervix. The cancer cells form continuous fields, type A cells (1); type B cells — considerable decrease in the DNA content of the nucleus and the RNA content of the cytoplasm, large nucleoli, rich in RNA and possibly several in number (2); type A_1 cells (3); mitoses (4). Fixing agent, Carnoy's fluid. Stained by Unna's method.

An identical phenomenon was also observed in the material from carcinoma of the breast: in adenocarcinoma type A₁ and type A cells were predominant, and in scirrhous and encephaloid carcinoma cells of types A₁, A and B were found, type A cells being predominant in the scirrhous form. In solid carcinoma type A and type B cells were most often found, and type A₁ cells less so.

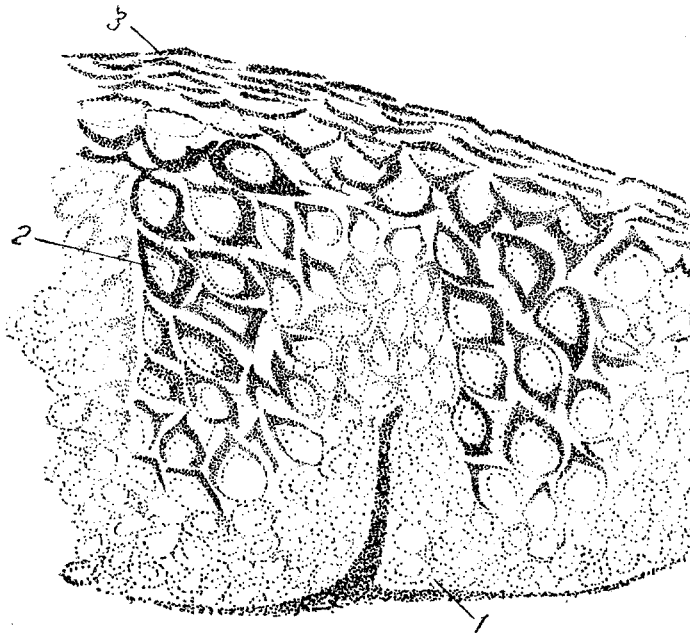


Fig. 2. Carcinoma "in situ" of the uterine cervix. Intra-epithelial infiltration of carcinoma cells; the cytoplasm of the cells contains no polysaccharide or an insignificant amount of it (1); the intervals between the carcinomatous infiltrations are filled with epithelial cells, the cytoplasm of which is rich in polysaccharides; intercellular bridges are seen (2), stratum corneum (3). Fixing agent, Carnoy's fluid. Stained by the Shabadash — Hotchkiss method.

The initial processes of malignant change were thus characterized by the accumulation of DNA in the cell nuclei. Type A₁ cells may be used as one of the early signs of malignant tissue. As the process of malignant change developed and the degree of malignancy increased, there was a growth of RNA synthesis in the tumor, as was shown by the increase in the number of type A cells.

In the dying cancer cells, destruction of DNA and RNA was observed; the latter was preserved mainly in the nucleolus, so that an increased number of type B cells was seen.

When stained by the Shabadash — Hotchkiss method, the cancer cells were found to be poor in or completely devoid of polysaccharides. A definite quantitative relationship was found to exist, opposite to that which was observed in respect to the nucleic acids: the peripheral cells of the tumor were poorest of all in polysaccharides, and their content in the central cells grew.

In carcinoma "in situ" of the uterine cervix the intra-epithelium infiltrations of carcinoma cells contained no polysaccharides, but the intervals between them were filled with epithelial cells, rich in polysaccharides (Fig. 2).

Thus at an early stage of malignant change, during the formation of foci of carcinoma, the surrounding tissue responded by a sharp rise in the content of polysaccharides in the cytoplasm. As the process developed, the polysaccharides were probably used up and nucleic acids were accumulated. In degenerating areas of the tumor, destruction of the nucleic acids took place and polysaccharides were once again accumulated.

SUMMARY

The author determined the content of nucleic acids, proteins and polysaccharides in the cells of cancer tumors of the human breast gland and uterine cervix by the cytochemical method. The data obtained were compared with the normal values. Biopsy material and organs removed during operations were examined. Cancer cells differ from the normal ones by a much higher nucleic acid and low polysaccharide contents.

Analysis of various cancer forms demonstrated a number of regularities, which may be an aid for the early diagnosis of cancer tumors in the future.

LITERATURE CITED

- [1] A. A. Grushina, *Voprosy Onkol.*, 1, No. 4, 51-59 (1955).
- [2] S. E. Bresler, *Uspekhi Sovremennoi Biol.*, 30, 1(4), 90-112 (1950).
- [3] L. F. Larionov, A. V. Kantin, *Vestnik Rentgenol. i Radiol.*, No. 1, 9-15 (1955).
- [4] E. E. Pogossyants, *Advances in Medicine*, No. 8, pp. 86-90, Moscow, 1948 [In Russian].
- [5] G. I. Roskin, A. A. Yulius, *Ark. Anat., Gistol. i Ėmbriol.*, 32, No. 4, 19-22 (1955).
- [6] A. I. Serebrov, *Carcinoma of the Uterus*, Leningrad, 1957 [In Russian].
- [7] Ya. G. Ėrenpreis, *Transactions of the Institute of Experimental Medicine of the Academy of Sciences of the Latvian SSR*, vol. 8, pp. 143-148, 1955 [In Russian].
- [8] R. Brett and O. Braun-Falco, *Arch. Dermat. u. Syph.*, 1955, Bd. 200, p. 515-520.
- [9] T. Caspersson and L. Santesson, In the book: *Acta Radiologica*, Suppl. Stockholm, 1942, v. 46.
- [10] T. Caspersson, *Symp. Soc. Exper. Biol.*, 1947, N. 1, p. 127-151.
- [11] T. Caspersson, *Cell Growth and Cell Function: A Cytochemical Study*. New York, 1950.
- [12] S. Hori, *J. Fac. Sc. Hokkaido Univ.*, 1956, Ser. 6, v. 12, N. 3, p. 425-431.
- [13] I. Kimura, *Japan. J. Cancer. Res.*, 1955, 6, N. 4, p. 549-566.
- [14] L. Lajos and K. Pali, *J. Obst. a. Gynec.*, 1951, v. 58, p. 780-783.
- [15] C. Leuchtenberger, *Exper. cell Res.*, 1956, v. 11, p. 506-507.
- [16] O. Warburg, *Über den Stoffwechsel der Tumoren*. Berlin, 1926.